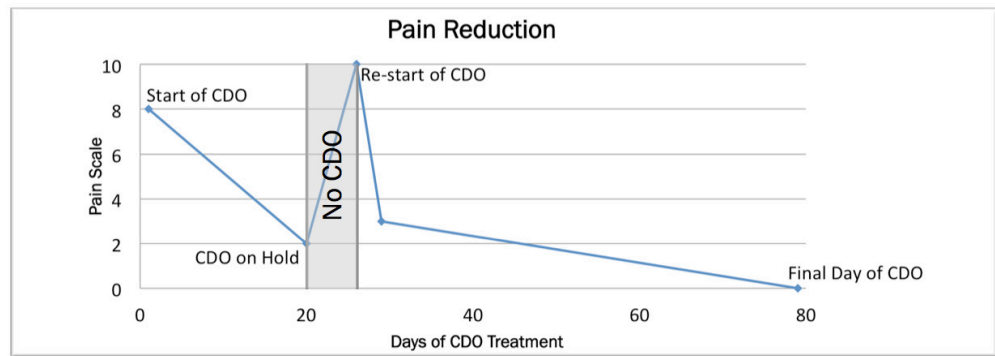


Case Study

Treatment of a Venous Leg Ulcer with CDO Therapy

Stephanie Wu, DPM, MSc, Chicago Illinois

- Patient: 53 year old female
- Wound History: Duration of ulcer prior to treatment with CDO was 5 months
- Medical History: History of venous insufficiency with ulcers bilaterally and obesity
- Previous Therapy: Profore compression*, Iodosorb*, Santyl* & silver nitrate
- Treatment: OxyGeni® set at 10 ml/hr using OxySpur® Oxygen Diffusion Dressing covered with Profore* 4-layer compression, Mesalt** used for hypergranulation control for 2 weeks
- Pain Reduction:
 - Prior to CDO, pain of 3 ranging as high as 8; intermittently taking pain medication
 - By 20 days of CDO, pain of 2 during dressing changes; no pain medication
 - On day 20, CDO therapy was placed on hold over a holiday
 - On day 26, patient returned to clinic reporting pain of 10 and difficulty sleeping; Patient needed to resume taking narcotic pain medication secondary to ulcer related discomfort; Patient resumed CDO therapy
 - 3 days after restarting CDO therapy, pain was controlled and patient was off narcotics

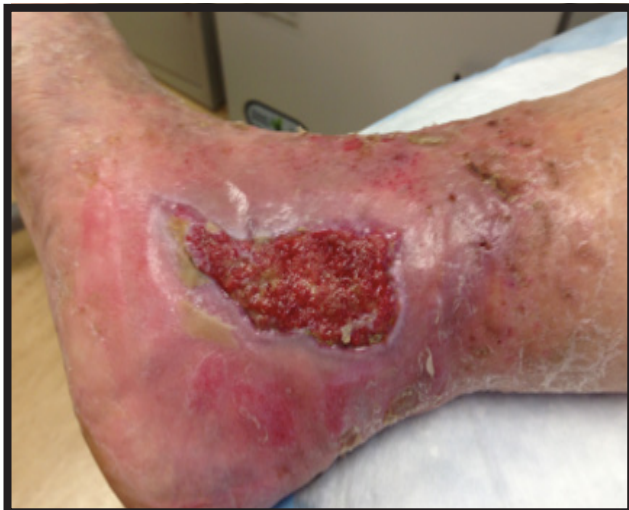

Summary: Wound closed in 79 days with 100% epithelialization over hypergranulation

Treatment Time

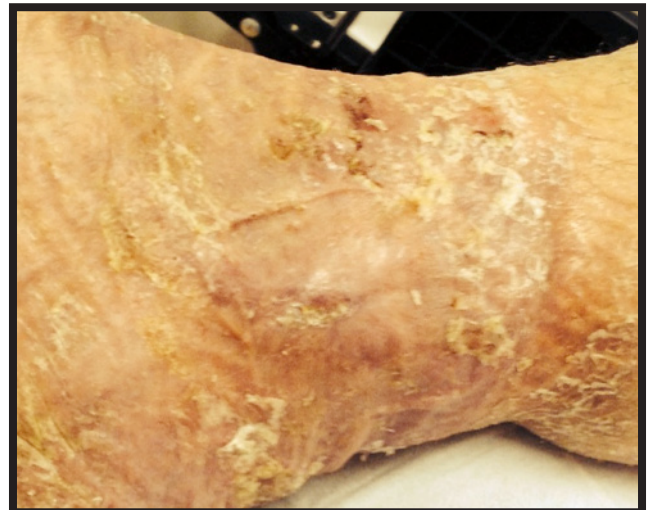

Day 0 - Initiation of CDO



Measurement: 6.7 x 5.3 with hypergranulation

Day 79 of CDO - Wound Closed



Epithelialization over hypergranulation

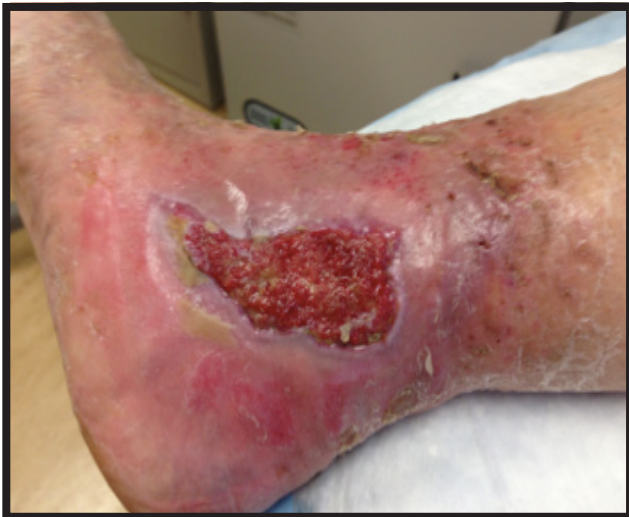

Case Study

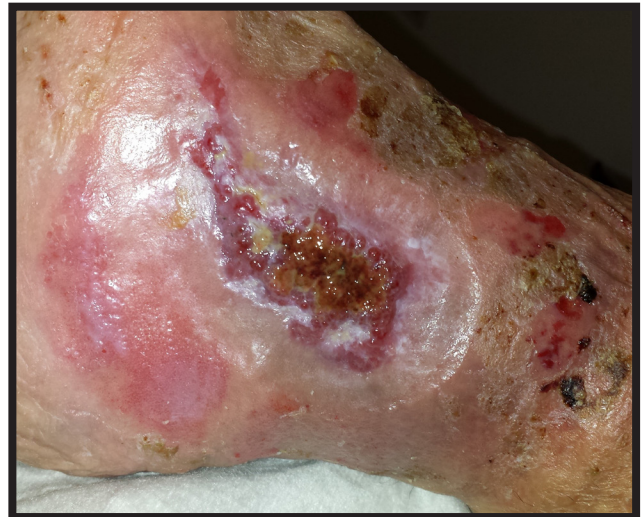Treatment of a Venous Leg Ulcer with CDO Therapy

Stephanie Wu, DPM, MSc, Chicago Illinois

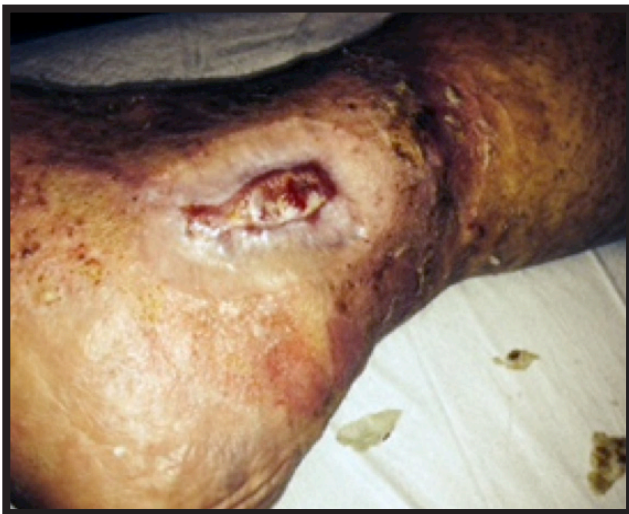(Photos courtesy of Stephanie Wu, DPM MSc, Associate Dean of Research, Dr. William M. Scholl College of Podiatric Medicine at Rosalind Franklin University of Medicine and Science, North Chicago, Illinois)



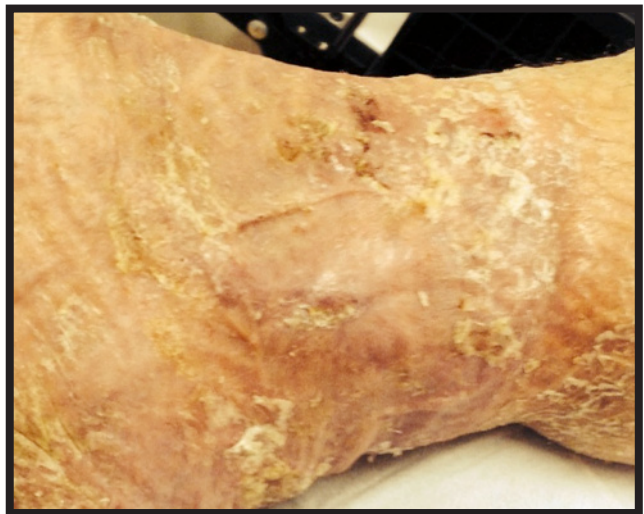Day 0 - Initiation of CDO
Measurement: 6.7 x 5.3 with hypergranulation



Day 29 of CDO



Day 54 of CDO
Measurement: 3.6 x 1.3 with hypergranulation



Day 79 of CDO - Wound Closed
Epithelialization over hypergranulation

Published in Podiatry Today
November 2014

